



# Clinical Case Presentation

Discussant: Prof Alexandre Karras



**Margarita Bora MD**

Nephrologist

**Aglaia Chalkia MD PhD**


Consultant Nephrologist

Nephrology Department

*Reference Center for Glomerular Diseases*

Hippokration General Hospital of Athens

# Case 1: Reason for Admission



61-year-old man with:

October 2021

- Purpura on lower legs
  - Gross hematuria
  - Anasarca edema
  
  - Abdominal pain
  - Anorexia
  - Low grade fever
  - Night sweats
- } past 4 months

# Case 1: PMH-Meds



## Past History

- Arterial Hypertension
- Benign Prostatic Hyperplasia (prostate biopsy negative)

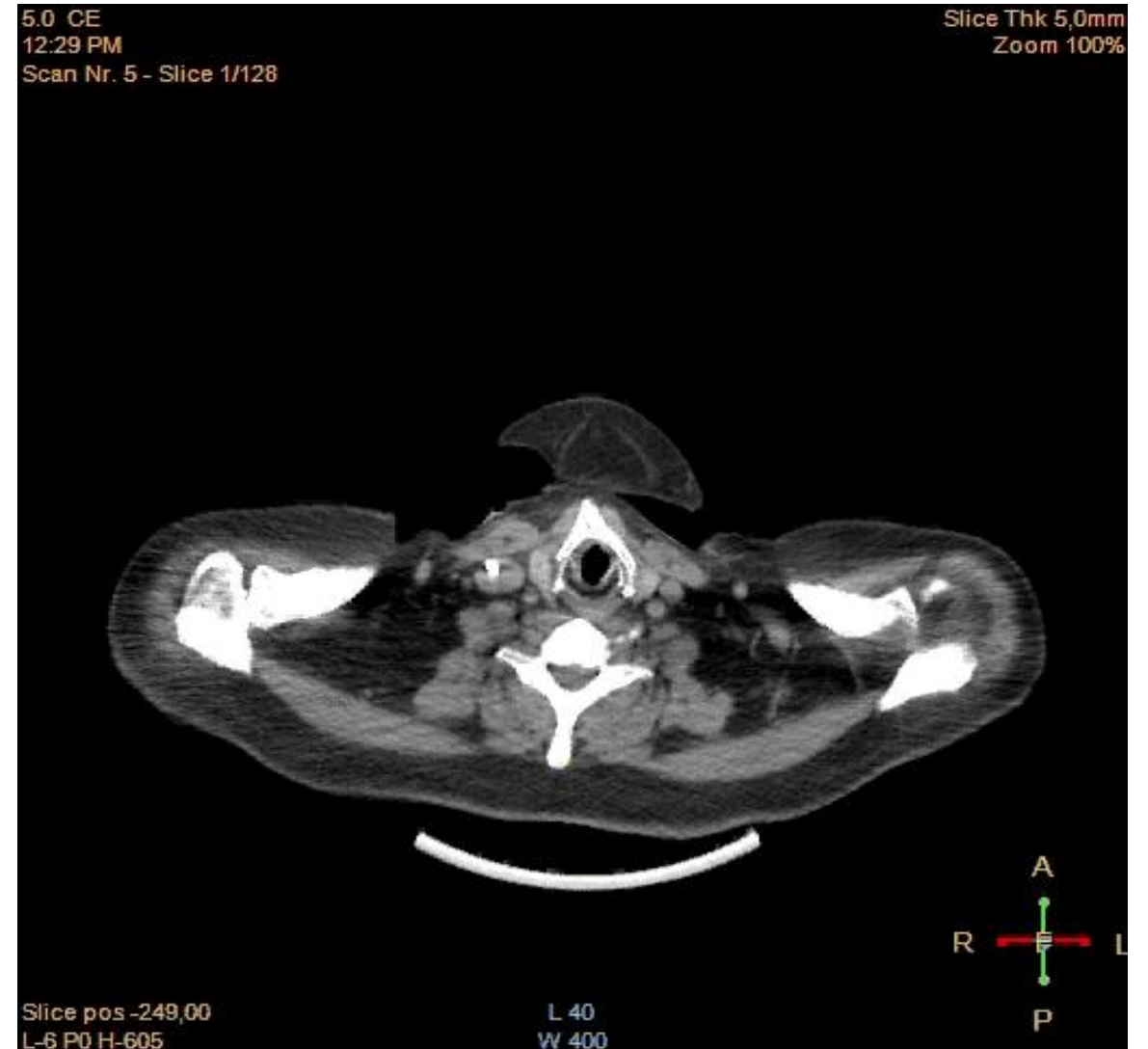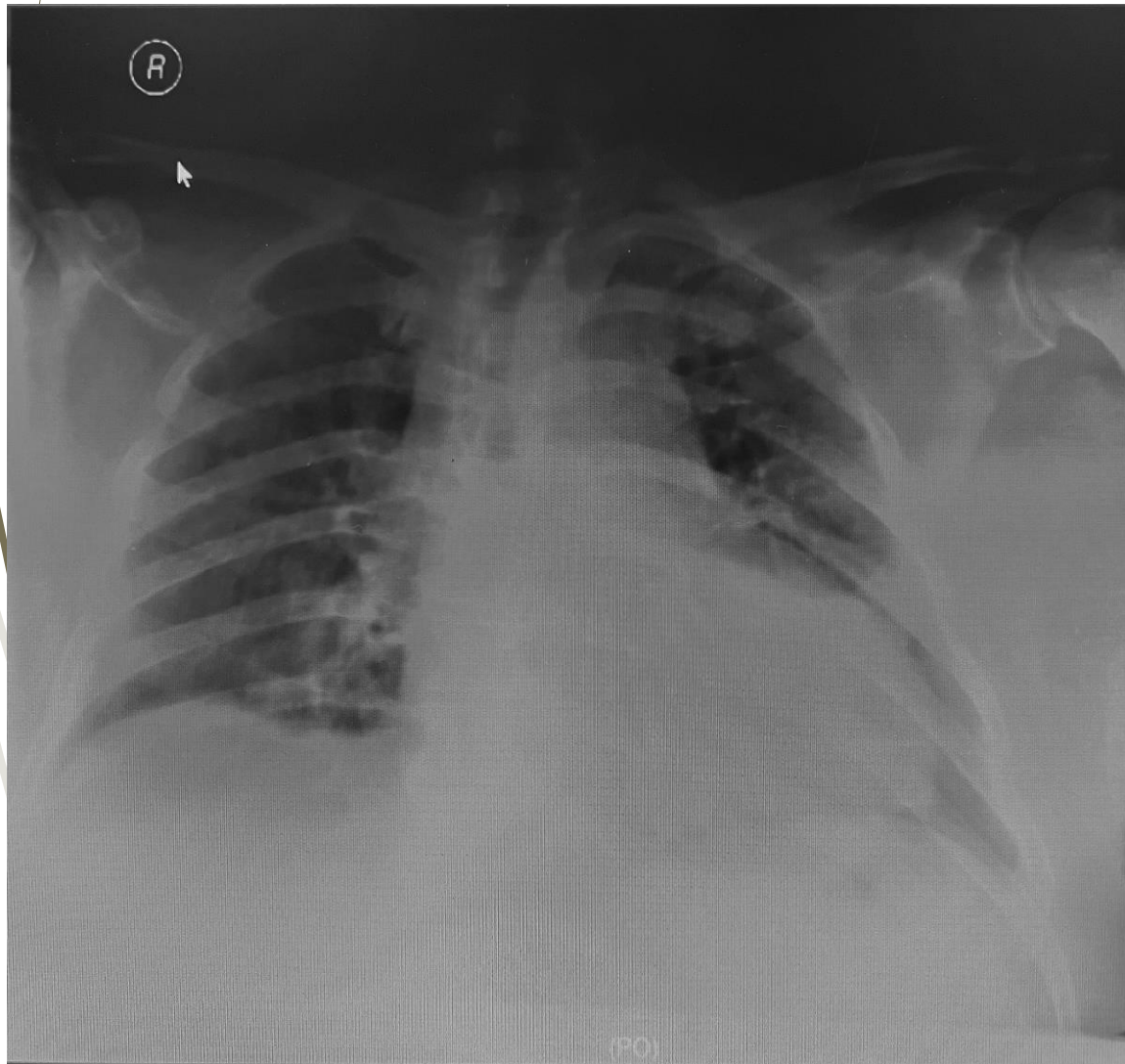
## Medications

- tb amlodipine 5mg 1x1
- tb alfuzosin 10mg 1x1

# Case 1: Initial Labs

<p>WBCs: 10,6 x10<sup>3</sup>/uL (neu 80%, lympho 9%) <b>Hb: 9,4mg/dl</b> Hct: 31,2% PLTs: 385 x 10<sup>3</sup>/uL</p>	<p><b>Cr: 5.6 mg/dL</b> <b>(eGFR=10 mL/min/1.73m<sup>2</sup>)</b> 3 mo ago: Cr: 0.9 mg/dL <b>Urea: 187mg/dL</b></p>	<p><b>CRP: 24 mg/L</b> <b>ESR: 77 mm/h</b></p>
<p>IgG: 572 mg/dL IgM: 27 mg/dL IgA: 169 mg/dL Ra test &lt;10</p>	<p><b>PR3-ANCA: 53.7 IU/mL</b> ANA (-)/anti- dsDNA (-) Anti-GBM (-) C3 :140 C4: 32</p>	<p>HBV,HCV: (-) HIV: (-) Quantiferon (-)</p>
<p><b><u>Urine analysis:</u></b> pH: 5,5 S.G.: 1016 <b>RBC/HPF: 50-60</b> WBC/HPF: 0-1 <b>Protein: 500 mg/dL</b></p>	<p><b><u>Urine sediment</u></b> <b>Dysmorphic RBC</b> <b>Red blood cell casts</b></p>	<p><b>24h protein: 5.600 mg</b></p>

# Case 1: Imaging studies



Pelvic lymph node biopsy



**Non-Hodgkin Lymphoma (small B-cell)**

# Case 1 - Summary

## **Kidney**

Glomerulonephritis

PR3ANCA+

eGFR < 15 ml/min  
hemodialysis dependent

## **Other systems**

Lung (nodules)

Skin (purpura)

PNS (Sensory  
peripheral  
neuropathy)

**NHL-B cell**

# Case 1: Renal Biopsy

- 11 glomeruli  
**11 (100%) with cellular crescents**  
8 (72%) with fibrinoid necrosis

- Mild interstitial inflammation

**Berden class: Crescentic**

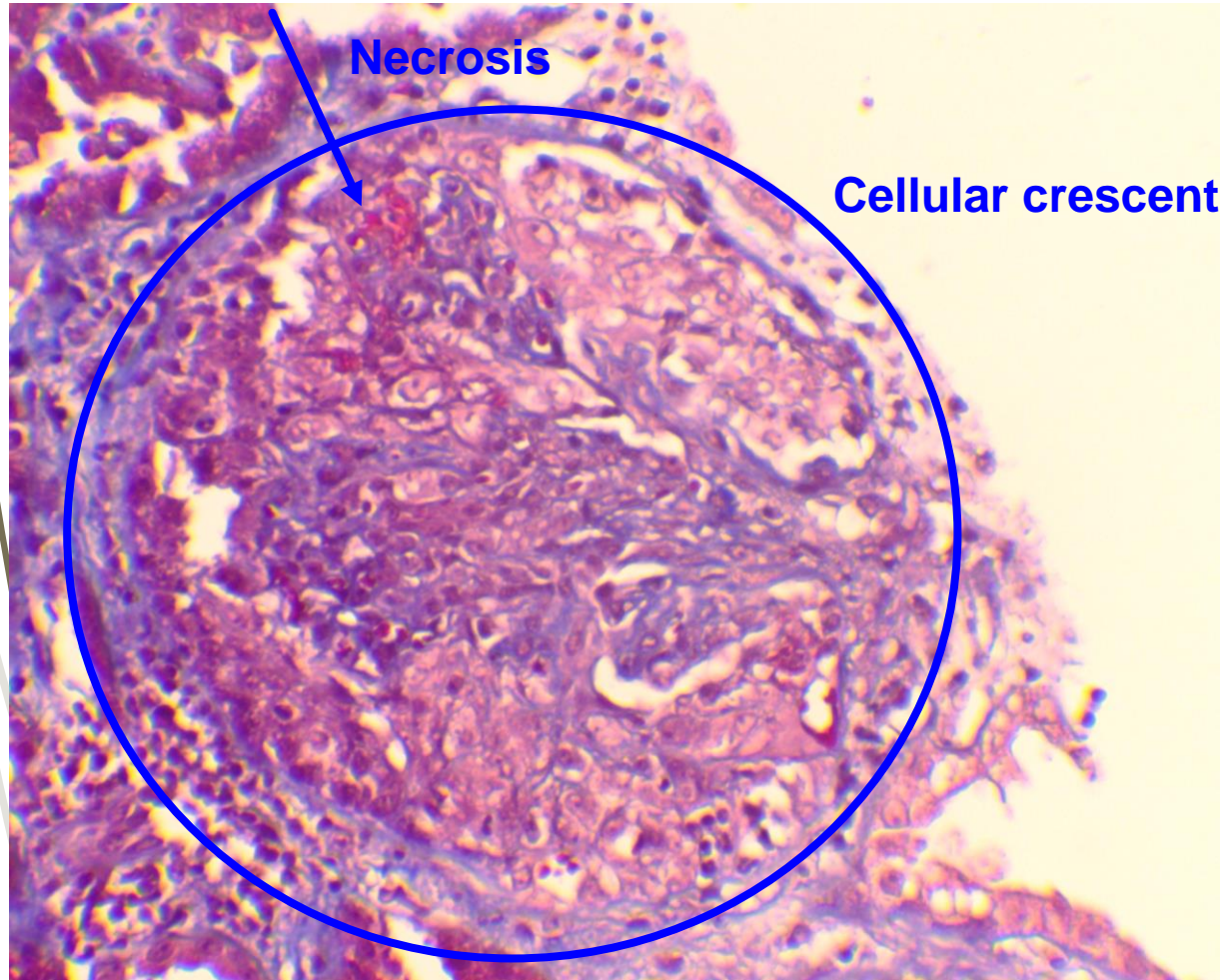
- 15% Interstitial fibrosis

**Brix score: High risk**

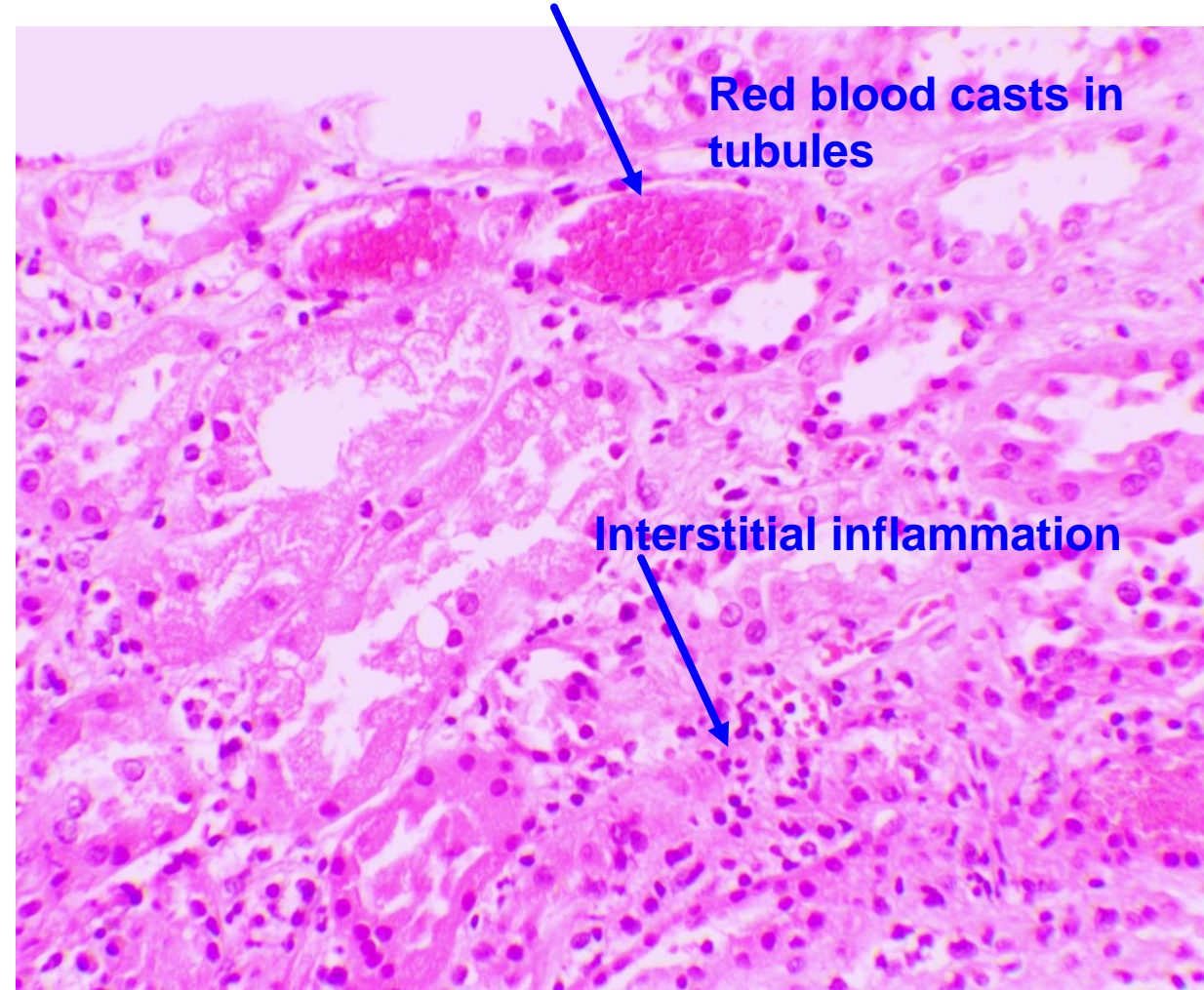
- Immunofluorescence: Negative

- Final pathologic diagnosis: **Pauci-immune crescentic necrotizing glomerulonephritis**

# Case 1: Renal Biopsy



Masson stain x200



HE x200

# Case 1: Final diagnosis

Severe GPA (PR3– ANCA+) with:  
kidney, lung, skin and peripheral nerve involvement

BVAS=26

&

NHL (Low grade B cell)

# Case 1: Question-1

- What should be the induction therapy for GPA?
- Would you add PLEX in this patient?

# INDUCTION THERAPY : proposal

Severe AKI with sCreat >350 =>

CYC or Combination CYC-RTX ( to discuss with hematologist)

Plasma exchange, based on  
sCreat kinetics. (rapidly progressing AKI)  
kidney biopsy findings (non major fibrosis)  
young age of the patient



# KDIGO 2024 Clinical Practice Guideline for the Management of Antineutrophil Cytoplasmic Antibody (ANCA)-Associated Vasculitis

*Kidney International 2024*

**Recommendation 9.3.1.1: We recommend that glucocorticoids in combination with rituximab or cyclophosphamide be used as initial treatment of new-onset AAV (1B).**

Rituximab preferred	Cyclophosphamide preferred
<ul style="list-style-type: none"> <li>• Children and adolescents</li> <li>• Pre-menopausal women and men concerned about their fertility</li> <li>• Frail older adults</li> <li>• Glucocorticoid-sparing especially important</li> <li>• Relapsing disease</li> <li>• PR3-ANCA disease</li> </ul>	<ul style="list-style-type: none"> <li>• Rituximab difficult to access</li> <li>• Severe GN (SCr &gt;4 mg/dl [354 μmol/l])*</li> </ul>

**Figure 7 | Factors for consideration when choosing between rituximab and cyclophosphamide for induction therapy of AAV. \*A combination of 2 intravenous pulses of cyclophosphamide with rituximab can be considered.** AAV, ANCA-associated vasculitis; ANCA, antineutrophil cytoplasmic antibody; GN, glomerulonephritis; PR3, proteinase 3; SCr, serum creatinine.

**Practice Point 9.3.1.6: Recommendations for oral glucocorticoid tapering are given in [Figure 9](#).**

**'Reduced-corticosteroid dose' in PEXIVAS trial**

**Practice Point 9.3.1.7: Avacopan may be used as an alternative to glucocorticoids. Patients with an increased risk of glucocorticoids toxicity are likely to receive the most benefit from avacopan. Patients with lower GFR may benefit from greater GFR recovery.**

**Practice Point 9.3.1.9: Consider plasma exchange for patients with SCr >3.4 mg/dl (>300 μmol/l), patients requiring dialysis or with rapidly increasing SCr, and patients with diffuse alveolar hemorrhage who have hypoxemia.**

# INDUCTION THERAPY : proposal

## **Personal point of view**

Points to consider when PLEX are discussed :

Presence of anti-GBM antibodies ?

Kinetics of sCreat ?

Extra-renal manifestations of AAV ?

Frailty/infectious risk of the patient ?

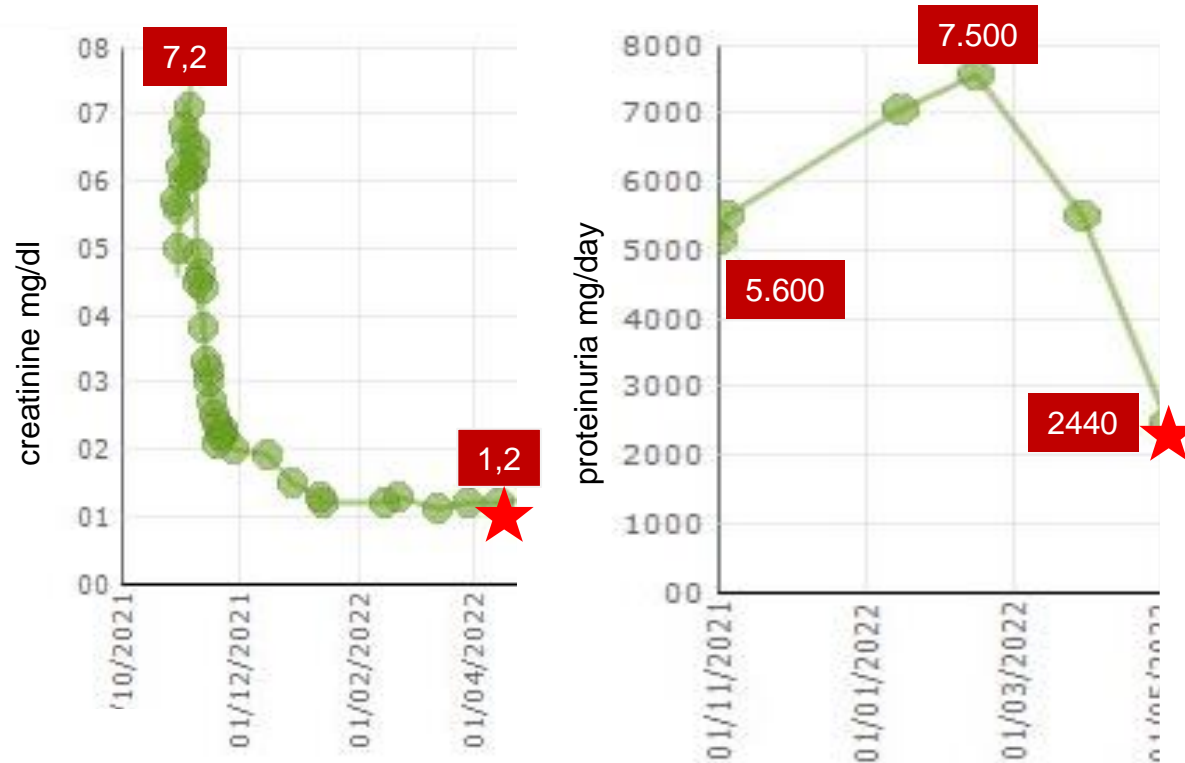
Result of kidney biopsy ?

Refractory AAV despite initiation of IS ?

# Case 1: Management

- **Combination RTX+CYC (R-CHOP regimen – per Hem/Onc)**
  - Cumulative dose CYC=7.6 gm
  - --//-- --//-- RTX=3.6 gm
- **Steroids**
  - IV methylprednisolone 1 gm/day x 3 days
  - PEXIVAS steroid regimen
- **PLEX**
  - 7 sessions

# Post-induction: 6 months



- PR3-ANCA (-)
- Lungs: Clear
- BVAS=0 / VDI=1
- Hematologic remission

## Question-2

What should be the maintenance therapy for this patient?

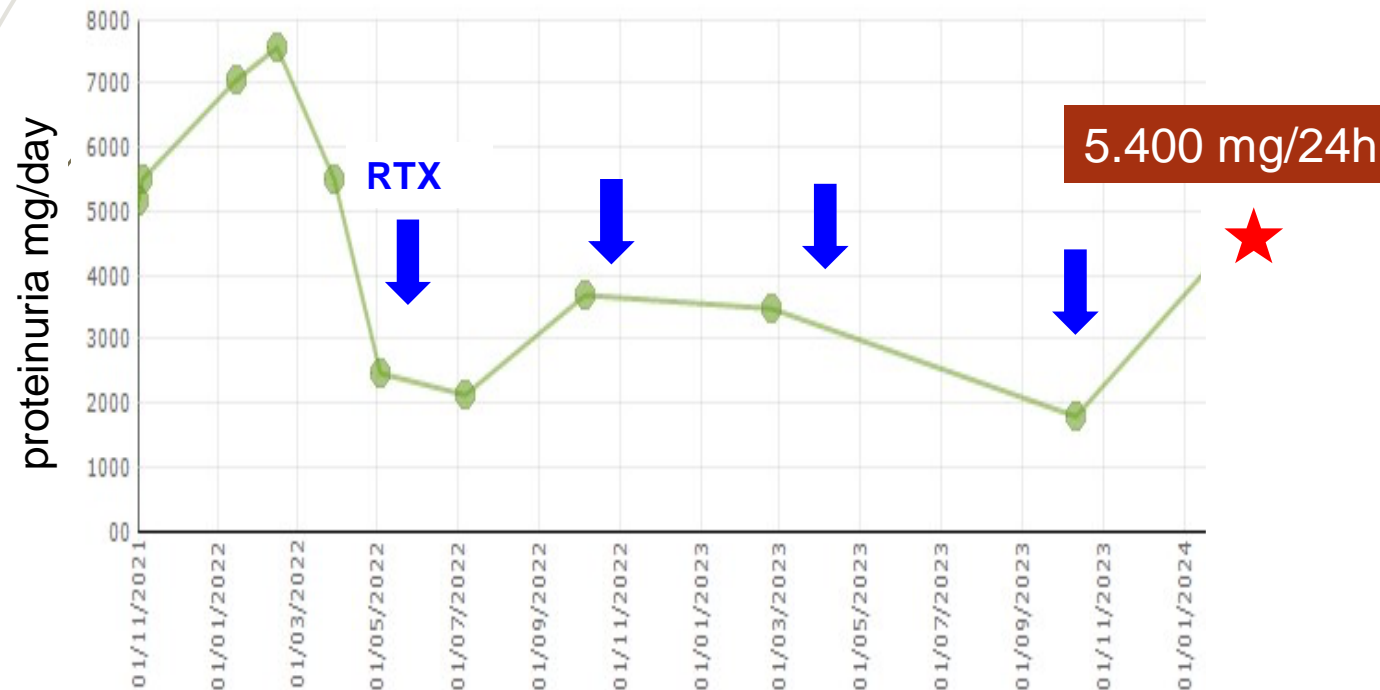
- A. MMF
- B. RTX
- C. AZA
- D. Low-dose steroids
- E. None

# Maintenance treatment

RITUXIMAB  
1gr/6mo

+ RASi / SGLT2i

After 24 months of treatment...



- Stable/normal renal function (eGFR:79 mL/min/1.73m<sup>2</sup>)
- Haematuria (-)
- PR3-ANCA (-)
- Hematologic remission
- **Proteinuria=5.400 mg/24h**

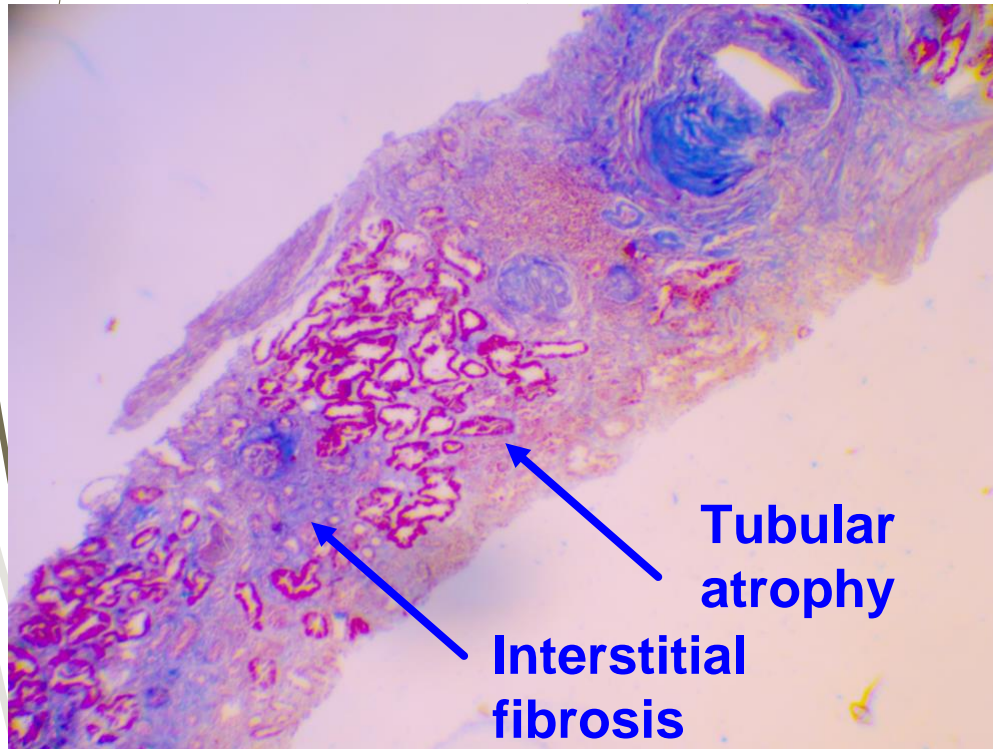
# Repeat renal biopsy (24 mo)

- 12 glomeruli  
50% global sclerosis (↑)  
**Fibrous crescents with few cells**  
25% segmental sclerosis (↑)  
15% normal glomeruli (↑)
- 30% interstitial fibrosis (↑)
- **Moderate interstitial inflammation (↑)**  
CD20, CD79a (-) (B cells)  
CD138, IgG4 (-) (plasma cells)  
**PGM1 (+) (macrophages)**  
**CD3 (+) (T cells)**
- Immunofluorescence: (-)

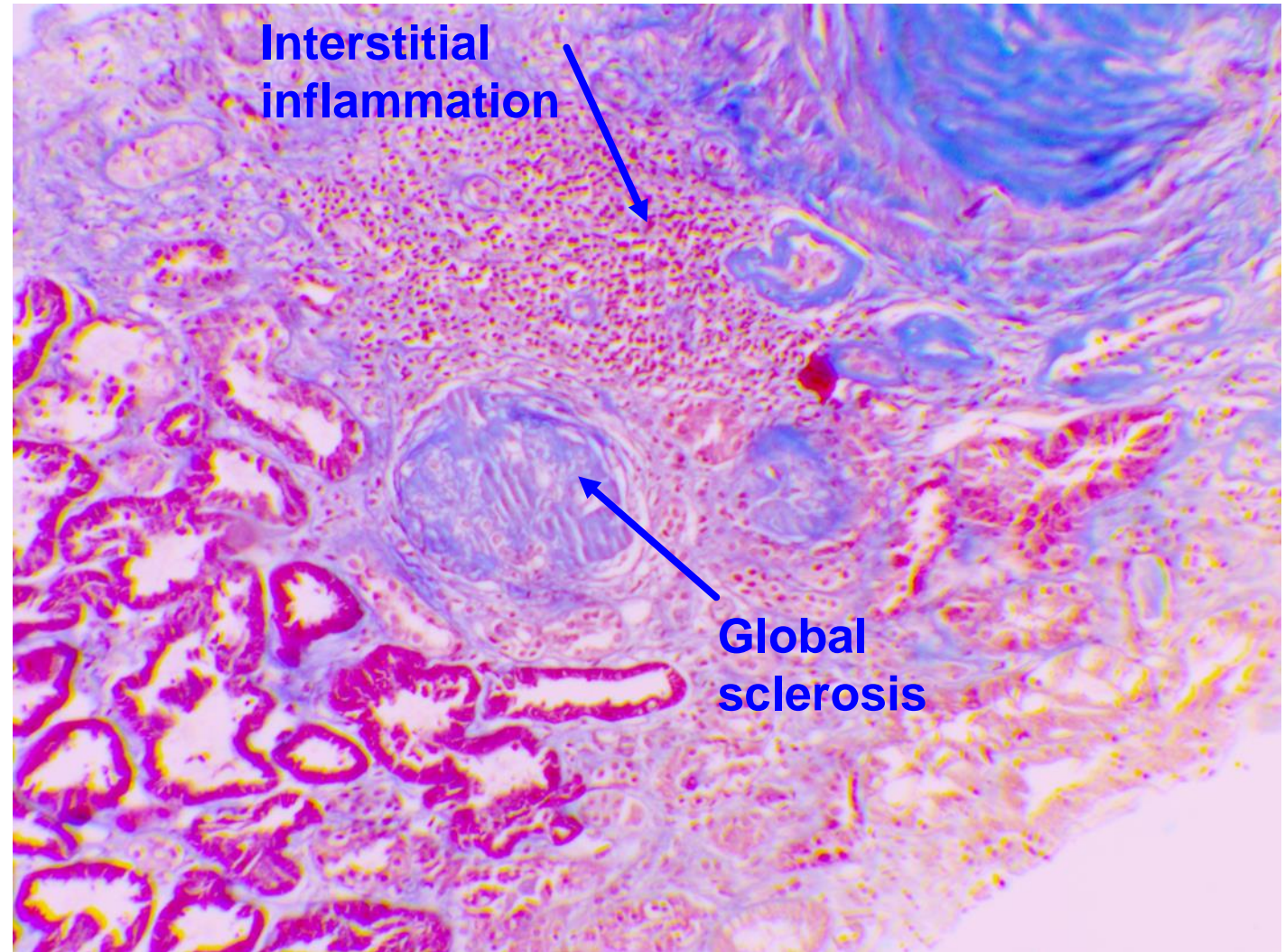
**Berden class: Sclerotic**  
(previous crescentic)

**Brix score: Moderate risk**  
(previous high risk)

# Repeat renal biopsy (24 mo)



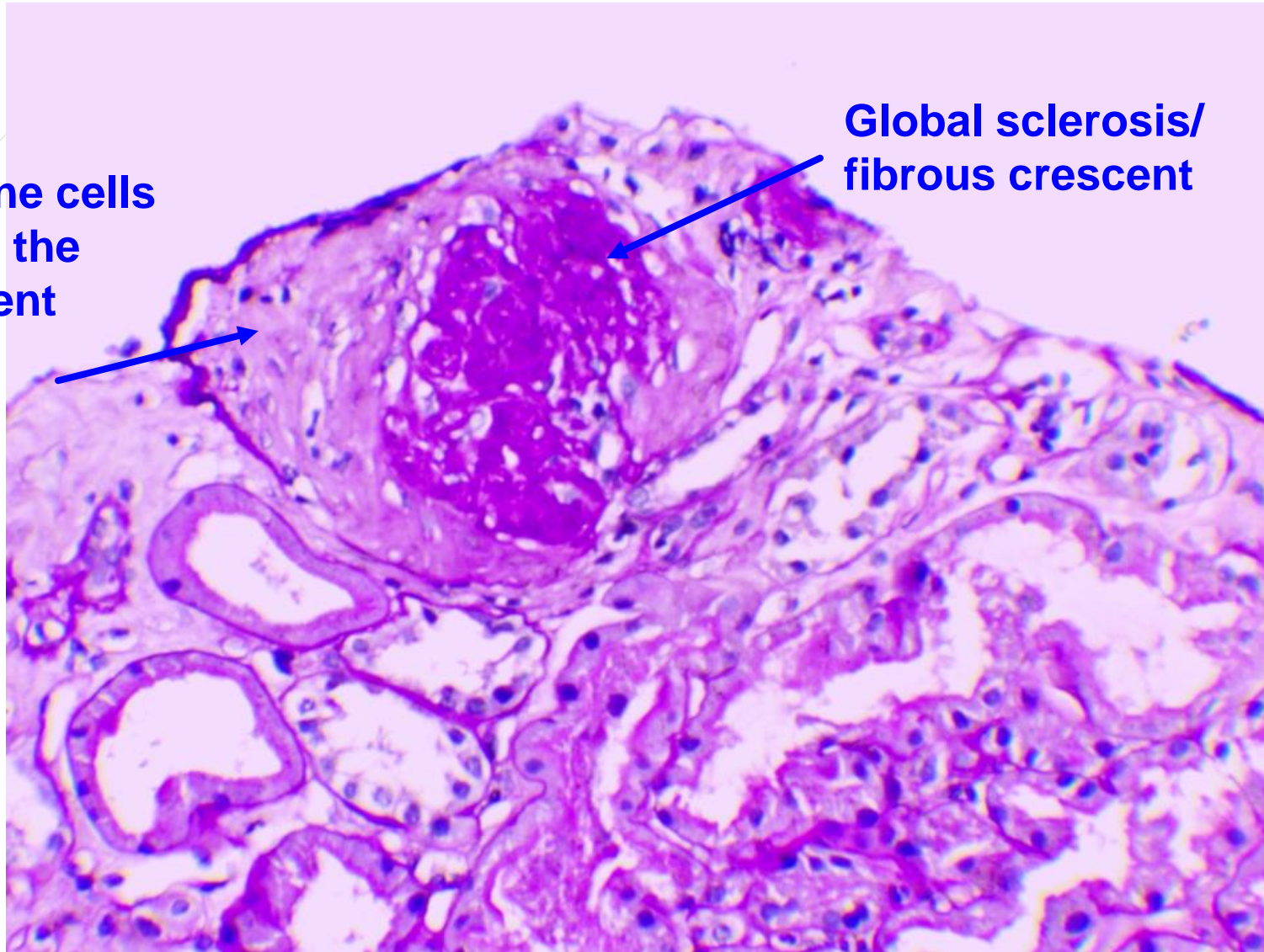
Masson stain x400



Courtesy of Harikleia Gakiopoulou MD, Aglaia Chalkia MD

# Repeat renal biopsy (24 mo)

**Immune cells  
inside the  
crescent**



**Global sclerosis/  
fibrous crescent**

Courtesy of Harikleia Gakiopoulou MD, Aglaia Chalkia MD

# Management issues

- **NHL:** Remission
- **GPA:**
  - Systemic involvement: Remission
  - Kidneys: Chronic low-grade inflammatory activity  
Chronicity (renal bx)  
↑↑ proteinuria
  - Serology: ANCA (-)

## Question-3

**What should be the next management step?**

- A. Continuation of current scheme (RTX 1gm q6mo)
- B. Re-induction with RTX (2 gm)
- C. Switch to MMF maintenance
- D. Addition of avacopan

# RE-INDUCTION FOR RELAPSE ?

Should we consider this situation as a relapse ?

No extra-renal activity

ANCA negativity

Stable sCreat, no hematuria

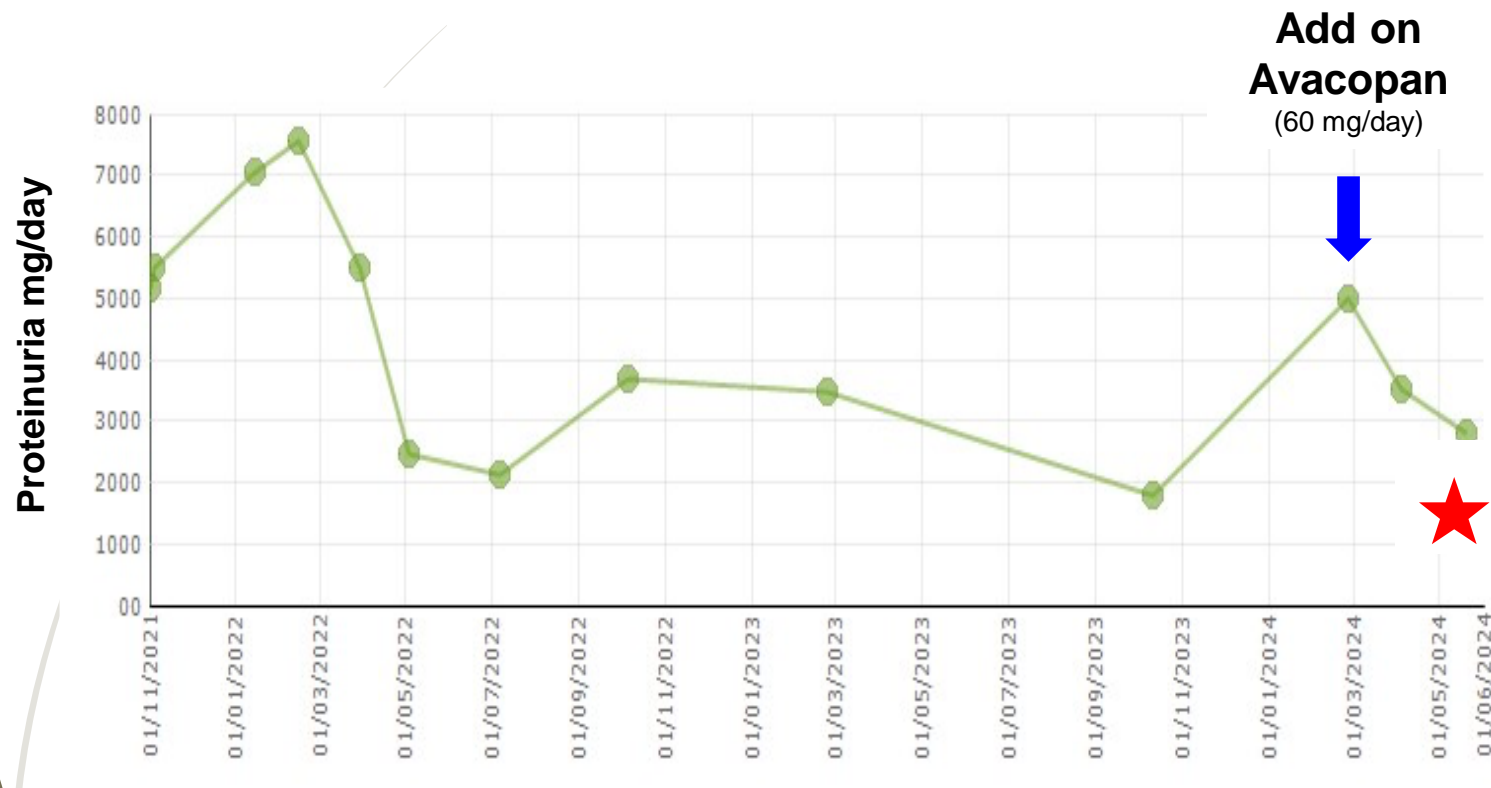No glomerular necrotic lesions on biopsy

BUT fibrocellular crescents and increased proteinuria

If you consider that the patient is relapsing => RTX re-induction and CS or avacopan

If you consider that there is no relapse => prolonged ANCA therapy until M48 (anti-PR3 with high relapse risk)

# Patient course



- Stable/normal renal function
- No side effects
- **1<sup>st</sup> mo: ↓ proteinuria by 20%**

# Acknowledgments

## **Nephrologists:**

Dimitrios Petras, Aglaia Chalkia, Margarita Bora, Elpiniki Stathopoulou, Georgios Aggelis

## **Rheumatologists:**

Dimitrios Vassilopoulos, Christos Koutsianas, Christina Tsalapaki

## **Hematologist:**

Flora Kontopidou

## **Pathologist:**

Harikleia Gakiopoulou



HELLENIC REPUBLIC

**National and Kapodistrian  
University of Athens**

EST. 1837

A decorative graphic on the left side of the slide consists of several thin, curved lines in shades of brown and grey, resembling stylized grass or reeds. These lines originate from the bottom left corner and curve upwards and to the right, extending across the top of the slide.

**Thank you for your attention**